Three dimensions of quantitative metamorphopsia measurement - do disease specific patterns exist ?

Daniela Claessens, MD, M.Sc.; Dipl.-Ing. Ronald Krüger, M.A.; Dürener Str. 251; 50931 Cologne; Germany

Purpose

The computer based program AMD - A Metamorphopsia Detector® is a tool to document 3 metamorphopsia aspects: amplitude of distortion (d), excentricity (ε) and area (a). This study was performed to get an impression whether disease-specific patterns of those parameters may give a hint to the underlying pathology.

Material and Methods

The AMD - A Metamorphopsia Detector® program (patent pending) is based on the Amsler grid [1]. The patient straightens lines he monocularly perceives distorted [2] in a given distance depending on the screen size, so that the angle between two lines is 1°, controlled by ultrasound distance measurement. 3 dimensions of metamorphopsia are logarithmically measured and build a global index (GI). In 166 eyes of 166 patients (male 75 =, female = 91; age 36-97 years) best corrected visual acuity, Amsler Test, metamorphopsia measurement with AMD - A Metamorphopsia Detector® and SD-OCT (Cirrus, Zeiss) were performed, fluorescein angiography was performed as recommended by german guidelines and statements [3, 4]. Diagnoses were classified (Beckman classification [5]): neovascular age related macular degeneration (nvAMD) = 25, intermediate AMD with large drusen (iAMD-dru) = 30, intermediate AMD with abnormalities of retinal pigment epithelium associated with at least medium drusen (iAMD-RPE) = 20, geografic atrophy = 9, retinal pigment detachment = 6, diabetic macular edema (DME) = 12 (4 with, 8 without neuro-sensory retinal detachment), epiretinal gliosis = 34, macular edema due to venous thrombosis (vtME) = 6, uveitis = 9 or myopia = 3 respectively, vitelliform maculopathy = 5, central serous chorioretinopathy (RCS) = 3, macular hole = 4. Prior to the study all patients signed informed consent according to the declaration of Helsinki/ Edinburgh.

Literature

1. Amsler M., Ophthalmologica, 1946. 112: p. 51.
2. Midena E. and Vujosevic S., Metamorphopsia: An Overlooked Visual Symptom. Ophthalmic Res, 2015. 55(1): p. 26-36.
3. Pauleikhoff D., Bertram B., Claessens D., Stellungnahme der Deutschen Ophthalmologischen Gesellschaft, der Retinologischen Gesellschaft und des Berufsverbandes der Augenärzte Deutschlands zur Therapie der chorioidalen Neovaskularisation bei Myopie (Stand: März 2014). Klin Monbl Augenheilkd, 2014. 231(5): p. 548-553.
4. BVA, DOG, Leitlinie 21: Altersabhängige Makuladegeneration AMD. 2015.
5. Ferris, F.L., 3rd, et al., Clinical classification of age-related macular degeneration. Ophthalmology, 2013. 120(4): p. 844-51.
6. Taylor DJ, Hobby A.E., Binns A.M., Crabb D.P., How does age-related macular degeneration affect real-world visual ability and quality of life ? A systematic review. BMJ Open, 2016. Dec 2;6(12):e011504.

Results

GLOBAL INDEX GI

Mean and median for GI was highest in nvAMD.
nvAMD and vtME showed highest GI- and single dimension values.

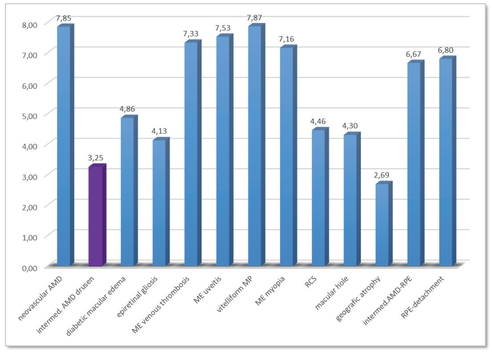

Fig. 1: Median Global Index (GI)

GI of nvAMD (median 7.85, mean = 7.41, CI = (6.6; 8.2)) and iAMD-RPE (median 6.67, mean = 6.88,CI = (6.1; 7.6)) were significantly higher than iAMD-dru (median 3.25, mean = 3.32, CI = (2.8; 3.8)): (t-Test, unlinked samples, $p < 0.001$).

Diagnosis	Mean GI
neovascular age related macular degeneration (nvAMD)	7.41
retinal pigment epithelial detachment	6.89
intermediate AMD with abnormalities of RPE (iAMD-RPE)	6.88
intermediate AMD with large drusen (iAMD-dru)	3.32

Table 1: Mean GI

CORRELATION OF SINGLE DIMENSION AND GLOBAL INDEX

Strongest correlation of single dimension and GI was found in nvAMD for amplitude of distortion (d) (Pearson correlation coefficient ρ = 0.95), in iAMD-RPE for excentricity (ε) (ρ = 0.9) and in DME for area (a) (ρ = 0.97) demonstrating which single dimension contributed primarily to the global metamorphopsia index (GI).

Diagnosis	N	GI	d	ε	a	d/a
neovascular AMD	25	7.85	4.14	2.36	1.87	2.04
RPE detachment	6	6.8	3.51	2.21	1.94	1.84
intermed. AMD-RPE	20	6.67	3.66	2.48	1.66	2.19
intermediate AMD drusen	30	3.25	1.95	1.05	0.69	2.33
geografic atrophy	9	2.69	1.61	0.96	0.69	2.33
diabetic macular edema	12	4.86	2.74	1.7	1.3	2.15
epiretinal gliosis	34	4.13	2.48	1.33	1.1	2.36
ME venous thrombosis	6	7.33	3.74	2.57	1.98	2.35
ME uveitis	9	7.53	4.08	2.98	2.3	1.81
vitelliform MP	5	7.87	4.14	2.78	2.44	1.65
ME myopia	3	7.16	3.76	2.38	2.08	1.81
RCS	3	4.46	2.71	1.31	1.1	2.46
macular hole	4	4.3	2.71	1.72	0.68	3.98

Table 2: Median GI and single dimensions d, ε and a

3 DIMENSIONS OF METAMORPHOPSIA

Median for amplitude (d) was highest in nvAMD and in vitelliform maculopathy (both 4.14)
Median for excentricity (ε) was highest in macular edema due to uveitis (ME uv) (2.98).
Median for area (a) was highest in vitelliform maculopathy (2.44) and in macular edema due to uveitis (ME uv) (2.30).
nvAMD revealed higher values than intermediate AMD with drusen or RPE-abnormalities in all 3 subindices.

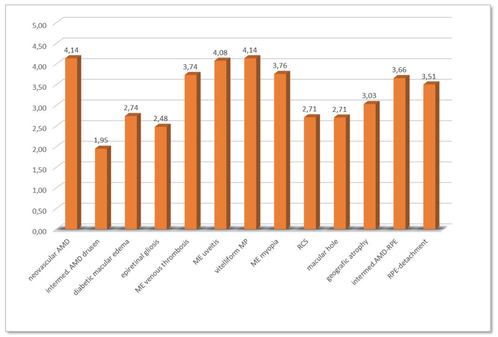

Fig. 2: median amplitude of distortion (d)

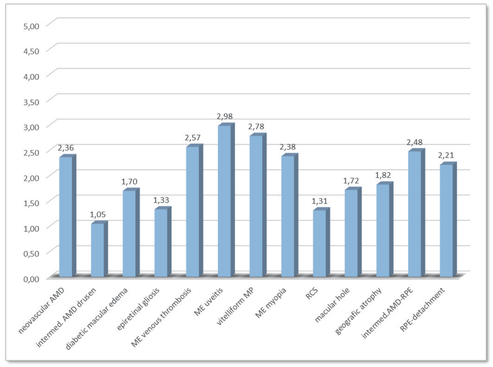

Fig. 3: median excentricity (ε)

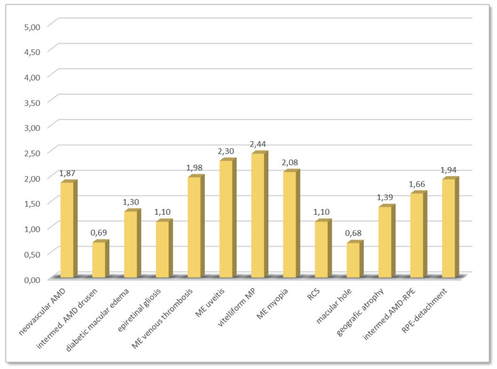

Fig. 4: median area (a)

LOCAL DEGREE OF DISTORTION

Diagnosis	Mean d/a	Median d/a
neovascular age related macular degeneration (nvAMD)	2.43	2.04
retinal pigment epithelial detachment	1.86	1.84
intermediate AMD with abnormalities of retinal pigment epithelium associated with at least medium drusen (iAMD-RPE)	2.34	2.19
intermediate AMD with large drusen (iAMD-dru)	3.18	2.33

Table 3: Local degree of distortion

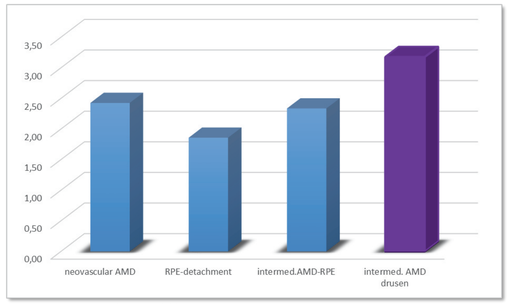

Fig. 5: mean local degree of distortion (d/a)

The smallest value for local degree of distortion (d/a) was found in vitelliform maculopathy (1.65), the highest in macular hole (3.98).
Local degree of distortion (d/a) was higher in intermediate AMD with large drusen (iAMD-dru) (d/a: mean 3.18, median 2.33) than in intermediate AMD with abnormalities of retinal pigment epithelium (iAMD-RPE) (d/a: mean 2.34, median 2.19) and in neovascular age related macular degeneration (nvAMD): (d/a: mean 2.43, median 2.04).

Conclusion

The AMD – A Metamorphopsia Detector® program provides quantitative evaluation of 3 dimensions of metamorphopsia as a patient relevant outcome [6]. Global Index, subindices and local distortion could distinguish intermediate AMD with drusen (iAMD-dru) from intermediate AMD with abnormalities of retinal pigment epithelium (iAMD-RPE), neovascular AMD (nvAMD) and RPE-detachment (fig. 1, 5, 6).

Presentation Number - Posterboard Number: 14- A0002
Session Number:104
Session Title: AMD imaging 1
Session Date / Times: May 07, 2017, 8:30 AM - 10:15 AM
Commercial Relationships Disclosure:
Daniela Claessens: Commercial Relationship(s);app4eyes: Code I (Personal Financial Interest), Code C (Consultant), Code P (Patent)
daniela.claessens@app4eyes.de
ronald.v.krueger@app4eyes.de

Discussion

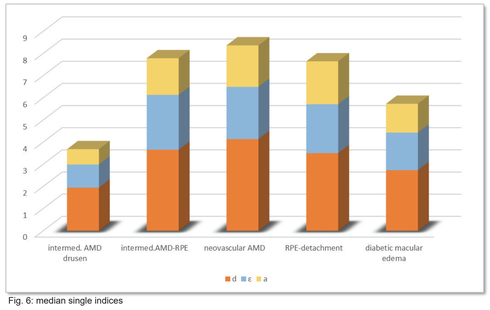

Fig. 6: median single indices

In this cohort neovascular AMD, retinal pigment epithelial detachment and intermediate AMD with abnormalities of retinal pigment epithelium respectively differed from intermediate AMD with large drusen in global index GI, subindices and local degree of distortion.
The fact that global index of neovascular AMD, retinal pigment epithelial detachment and intermediate AMD with abnormalities of retinal pigment epithelium respectively were significantly higher than intermediate AMD with large drusen could be an indicator that macular anatomical deterioration is accompanied by enhancement of metamorphopsia.
Different group sizes is a bias.
Calculation of local degree of distortion (d/a) revealed higher mean and median values in intermediate AMD with large drusen (iAMD-dru) than in intermediate AMD with RPE-abnormalities (iAMD-RPE), RPE-detachment and neovascular AMD (nvAMD) (Tab.3)
Higher local distortion values and lower GI values distinguished intermediate AMD with large drusen (iAMD-dru) in this study from neovascular AMD (nvAMD), intermediate AMD with RPE-abnormalities (iAMD-RPE) and RPE-detachment. Increasing GI and decreasing d/a may therefore indicate the need for close-meshed controls. Data of a larger cohort may reveal if changes over time leading to retinal pigment epithelium abnormalities and finally macular edema are accompanied by increasing global index and/or subindex values and decreasing local distortion (d/a) values and might thus be an indicator for impending conversion to neovascular AMD.
Typical patterns of global index, single dimensions and amplitude peaks emerging from such a study could serve as a diagnostic hint.